

MANAGEMENT OF CO-EXISTING CATARACT & GLAUCOMA

M.I. ABDALLA, F.R.C.Ophth.

PRESIDENT, E.S.G.

HISTORICAL BACKGROUND

At the beginning of the last century, we were dealing with the problem of glaucoma and cataract in different ways than we now do. As for the medical treatment of POAG and PACG we were only practicing the use of parasympathetic nerve transmitters, local medications; mainly Pilocarpine in different concentrations to be used 3-4 times per day. With knowledge of the presence of receptors, a new era in the medical management of glaucoma, a train of new hypotensive drops came into practice: Beta Blockers, Alpha Agonists, local carbonic anhydrase inhibitors and lately, Prostaglandin analogues to be used twice or even once per day and, accordingly, patient compliance became possible, facilitating enormous improvement in the patient's quality of life. Moreover, the nightmare of surgical intervention could be temporarily postponed.

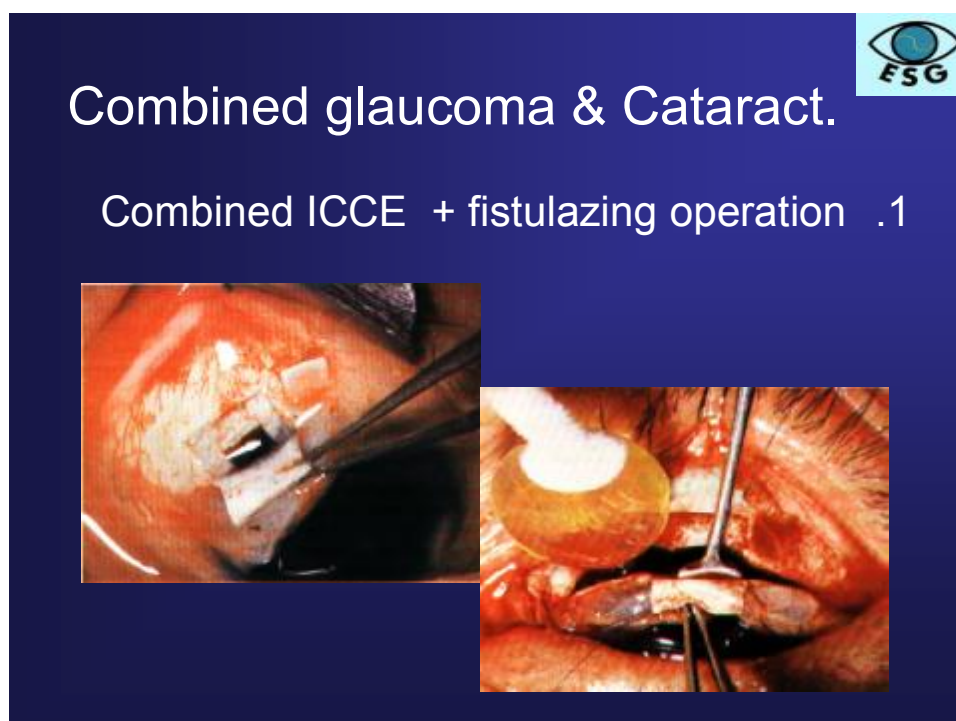

Fig 1: Combined ICCE with Subscleral Trabeculectomy

Past and present treatment of cataract was and is surgical; starting with extracapsular cataract extraction, intracapsular cataract extraction, with and without PMMA implant, then planned extracapsular cataract extraction and lately, phacomulsification, using Healon and soft intraocular lens implant.

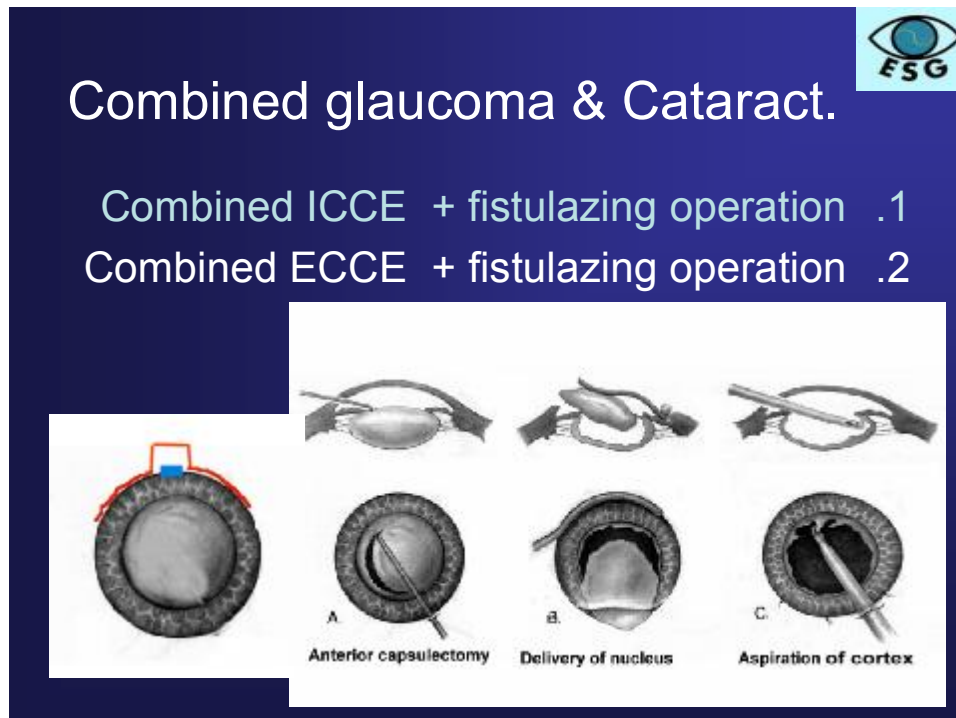


Fig 2: Planned ECCE with Subscleral Trabeculectomy

Coexisting glaucoma and cataract is a more frequent problem in the elderly. Recent clinical glaucoma trial data from AGIS the Advanced Glaucoma Intervention Study, (CIGTS) Collaborative Initial Glaucoma Treatment Study, EMGT the Early Manifest Glaucoma Trial, CNTGS the Collaborative Normal Tension Glaucoma Study and OHTS the Ocular Hypertension Study, all report that both medical and surgical treatment of glaucoma, increases the rate of cataract development. Surgical management of concomitant glaucoma and cataract is complex, given the large number of treatment options and technical approaches available.

Glaucoma and cataract are the two most common causes of vision loss in the elderly population. Cataract is the leading cause of reversible blindness in the world, whereas glaucoma is the leading cause of irreversible vision loss.

Because cataract is frequently observed in patients with glaucoma, patients with coexisting glaucoma and cataract face complex considerations in terms of their surgical management. The presence of cataract can affect the ability to assess glaucoma progression, and cataract extraction affects the intraocular pressure and effectiveness of glaucoma surgery.

Cataract & Glaucoma

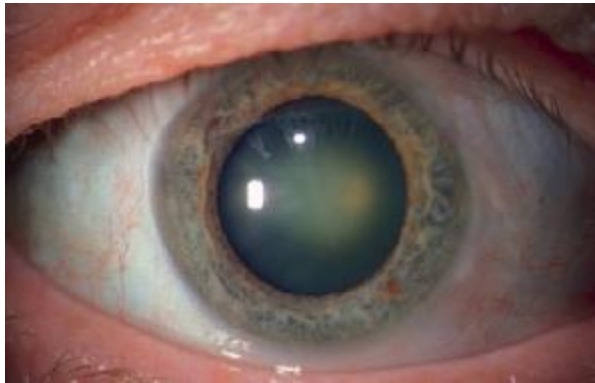


Fig. 3: Disc visualization

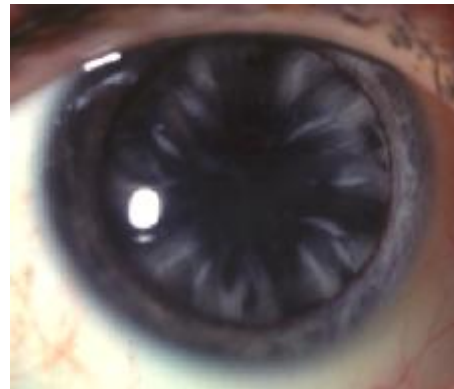


Fig. 4: Effect on field of vision

The treatment of glaucoma is a significant risk factor for the development of cataract.

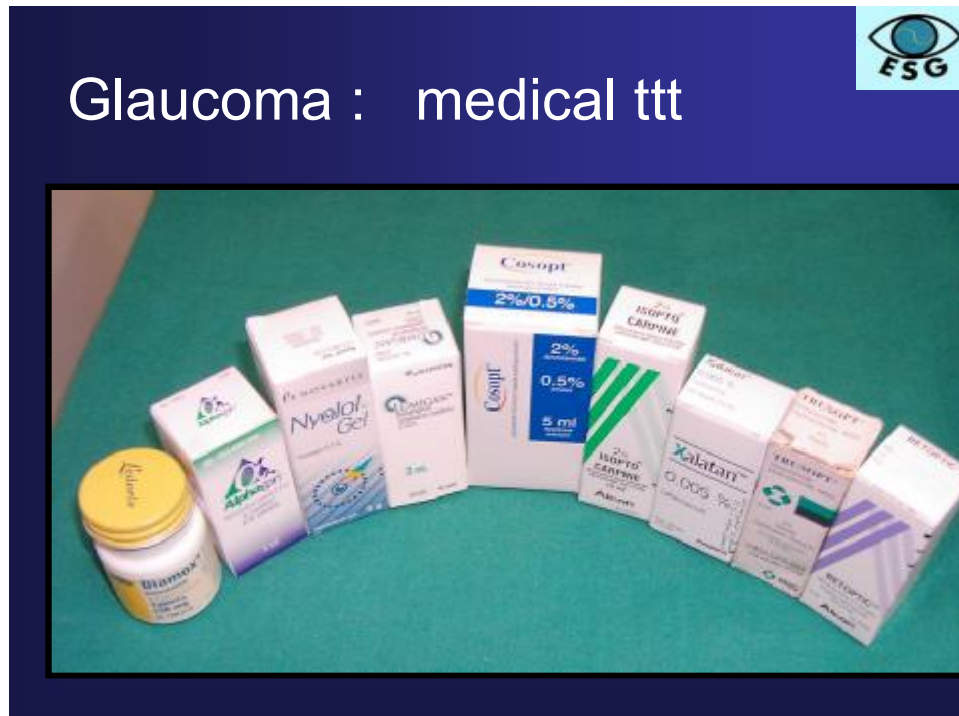The Collaborative Initial Glaucoma Treatment Study (CIGTS) studied patients who were randomized to either surgery or medical therapy for the initial treatment of newly diagnosed glaucoma. That initial treatment of glaucoma with surgery resulted in approximately twice the incidence of cataract requiring surgical management compared with the initial treatment of glaucoma with medications.

The Advanced Glaucoma Intervention Study (AGIS) found that patients, who failed medical therapy and underwent a defined surgical regimen for glaucoma treatment, reported a 78% increase in the risk of cataract formation after a single trabeculectomy compared with initial treatment with argon laser trabeculoplasty. Antimetabolite use was not shown to additively increase the risk of cataract formation compared to no antimetabolite use with trabeculectomy.

The Collaborative Normal-Tension Glaucoma Study (CNTGS) determined in the treated arm of the study, that 38% of the patients developed cataracts compared with 14% in the untreated group. The mean time to cataract formation was earlier in the surgically treated (168 days), compared with the medically treated groups (1266 days), providing strong evidence that glaucoma filtration surgery significantly increases the risk of developing cataract.

The Advanced Glaucoma Intervention Study, CIGTS and CNTGS study patients were surgically treated, predominantly with trabeculectomy phakic patients undergoing glaucoma drainage implant surgery and also having significantly increased incidence of cataract development. Thus current glaucoma surgery techniques commonly increase the rate and incidence of cataract formation.

Treatment of glaucoma with topical medications is also associated with the development of lens opacity. In the Ocular Hypertension Treatment Study (OHTS), risk of developing lens opacities was tripled in patients who were using topical glaucoma medications.



The Early Manifest Glaucoma Trial (EMGT) stated that the use of topical glaucoma medications increased the incidence and rate of development of lens

opacity, the reasons for which are not evident, but apparently are not specific to a particular medication and may be to physiological effect on the aqueous dynamics of glaucoma patients and the lowering of the intraocular pressure.

In summary both the medical and surgical treatment of glaucoma significantly increases the incidence of cataract development. How does glaucoma treatment, whether medical or surgical, affect the decision making process for combined or staged glaucoma and cataract surgery, given that glaucoma treatment increases the risk of cataract formation?

Concomitant cataract and glaucoma significantly complicate the decision making process for surgical management of these two ocular diseases.

The presence of cataract affects the sensitivity and reliability of visual field tests, especially short wavelength automated perimetry, which affects the decision to continue medical management of glaucoma versus considering surgery.

The presence of lens opacities affects visualization of the optic nerve necessary to determine nerve fiber loss and optic nerve cupping.

Anatomical narrow angles that increase the risk of narrow angle forms, can be widened by cataract surgery. Therefore, cataract surgery may improve not only a patient's activities of daily living and quality of life, but also the ophthalmologist's management of glaucoma. Glaucomatous visual field defects, especially those affecting fixation, can affect estimates of visual potential after cataract extraction. Significantly elevated IOP prior to cataract extraction increases the risk of operative complications such as suprachoroidal hemorrhage. In deciding to proceed with cataract extraction, visual potential needs to be assessed. The Potential Acuity Meter (PAM) and the Potential Acuity Pinhole (PAP) are quick to administer, and can be tested in any language using a near card, but PAP is preferable and more reliably accurate than the PAM.

Once the decision for cataract surgery has been made, whether or not concomitant glaucoma surgery is also necessary, patients with cataract and mild glaucomatous damage with good IOP control would benefit from cataract surgery alone and can undergo later glaucoma surgery. Combining glaucoma surgery with

cataract extraction minimizes the risk of a postoperative pressure spike and can improve long-term IOP control.

The decision to proceed with surgical management of coexisting glaucoma and cataract, require careful consideration of the patient's ocular history and necessitates balancing the risks and benefits associated with ocular surgery. In the patient with well controlled glaucoma who is advised to be treated with cataract surgery alone, the approach to cataract surgery must take into account the possible glaucoma surgery in the future. On the other hand, in the patient with prior glaucoma surgery, care must be taken to preserve function of the existing bleb or tube. In glaucoma patients pressure in the postoperative period must be minimized to prevent further compromise of the glaucomatous optic nerve.

Clear cornea, especially temporal, phacomulsification cataract surgery (PECE) is the preferred approach to maximize the options available should glaucoma surgery become necessary in the future. Retained viscoelastic can cause significant intraocular pressure spikes that may further compromise a glaucomatous optic nerve. Ideally, clear corneal temporal, phacoemulsification cataract surgery, should be performed in the presence of a superior filtering bleb.

Many reports suggest that cataract surgery alone can decrease IOP in glaucoma patients. Patients undergoing ECCE require additional glaucoma surgery for the IOP control more frequently than patients who underwent PECE. Certain views are held that manipulation during cataract surgery increases the risk of the intraocular pressure rise post-operatively. Subconjunctival scarring in the area of the bleb is also a great risk. The use of 5-fluorouracil (5-FU) and/or needle revision of the bleb might be of additional help.

Patients with glaucoma and minimal cataracts should not have cataract surgery unless they are visually handicapped. Patients with significant cataract who present with very high uncontrolled IOP should have staged procedures with filtering surgery first and then cataract surgery at a later date because of the increased risk of complications.

Glaucoma drainage implants are a good option compared with trabeculectomy, especially with inflammatory and neovascular glaucoma. Accordingly, the decision to perform cataract surgery in combination with glaucoma surgery needs to take into account the risk of diminished long term IOP lowering with glaucoma surgery, contrasted to the potential improved quality of life with cataract extraction. The decision to perform cataract surgery and glaucoma surgery together, using a single-site incision, leads to less control of the IOP post-operatively, compared with a 2-site approach or a drainage tube implant.

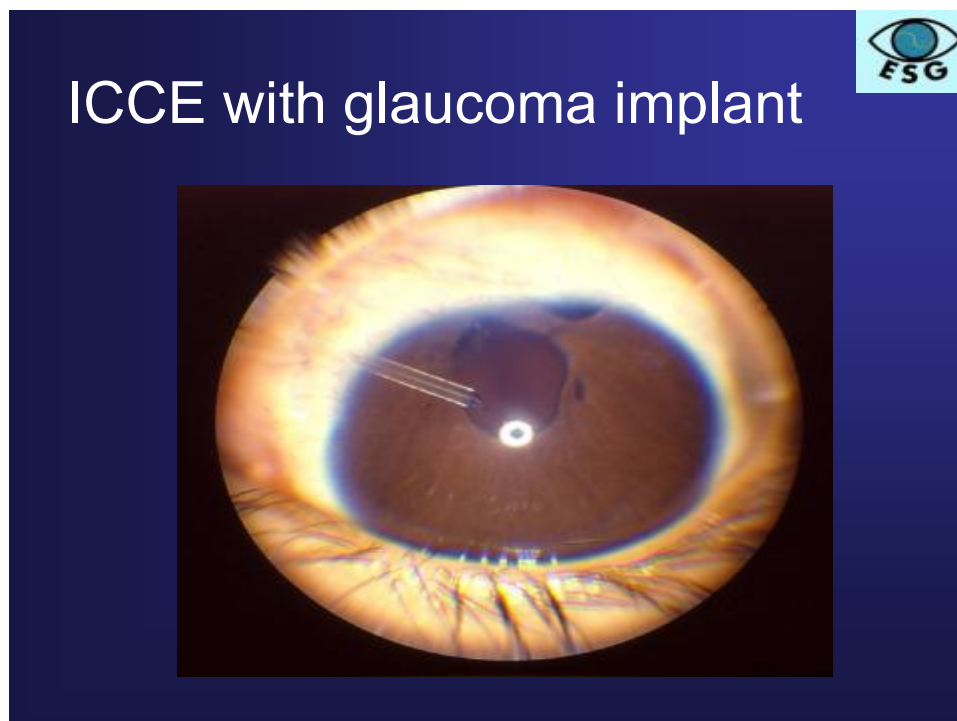


Fig 5: Intracapsular cataract extraction with glaucoma implant

Deep sclerectomy with collagen implant combined with PECE has been compared with combined PECE with trabeculectomy and the two groups had similar levels of IOP reduction and visual acuity outcomes.

Shoeir in a recent report, 2005 Egyptian Journal of Ophthalmology, concluded that phacoemulsification using a clear corneal incision away from the bleb site has minimal effect on the long term mean IOP and the morphology of the filtering bleb, but there is more than 8% incidence of failure of the bleb function after follow-up period of six months. For further reading, please refer to the International

Ophthalmology Clinics Publication, Vol. 44, no 2, Spring 2004, "Glaucoma – A Look at the Past, Present and Future".

For further reading, please refer to the International Ophthalmology Clinics Publication, Vol. 44 no 2, Spring 2004, "Glaucoma – a Look at the Past, Present and Future". Glaucoma News March issue 2005 vol. 5 no. 1.